

# A Patient Diagnosed with Allergic Contact Dermatitis and Pityriasis Rubra Pilaris

## Allerjik Kontakt Dermatit ve Pitriyazis Rubra Pilaris Tanılı Bir Hasta

Ümran Öner<sup>1</sup> , Handan Bilen<sup>2</sup> 

<sup>1</sup>Department of Dermatology, Bölge Training and Research Hospital, Erzurum, Turkey

<sup>2</sup>Department of Dermatology, Atatürk University Faculty of Medicine, Erzurum, Turkey

**Cite this article as:** Öner Ü, Bilen H. A Patient Diagnosed with Allergic Contact Dermatitis and Pityriasis Rubra Pilaris. Arch Basic Clin Res 2021; 3(2): 79-81.

**ORCID iDs of the authors:** Ü.Ö. 0000-0002-7119-9876; H.B. 0000-0001-6507-1406.

### ABSTRACT

Pityriasis rubra pilaris (PRP) is a rare papulosquamous disease with unclear etiology. There are six types of the disease, which can be identified according to the age of onset and the skin involvement observed. Type 3 (classic juvenile type), type 4 (circumscribed juvenile type) and type 5 (atypical juvenile type) are juvenile forms. Here, a 3-year-old girl diagnosed with Type 3 PRP was presented. At the first admission, the patient diagnosed with allergic contact dermatitis (ACD) induced by the lipstick was treated with topical therapies; and the patient recovered completely within a week. But she was readmitted due to a widespread rash throughout the body and palmoplantar keratoderma 10 days later. The results of the patient's skin biopsy confirmed the suspected diagnosis of juvenile PRP. We present a patient who presented with ACD and classic juvenile PRP after lipstick contact, and in this case, we think that the exposure to lipstick may have a role in the occurrence of PRP as in ACD.

**Keywords:** Contact dermatitis, cosmetics, pityriasis rubra pilaris

### INTRODUCTION

Allergic contact dermatitis (ACD) is a common disease that has been found to occur increasingly in children (1). Pityriasis rubra pilaris (PRP) is a rare, idiopathic, papulosquamous dermatosis. It commonly occurs in the first and the fifth decade of life (2), and adult and juvenile forms of the disease have been described. In this report, a patient who contracted ACD and juvenile PRP after lipstick contact is presented.

### CASE PRESENTATION

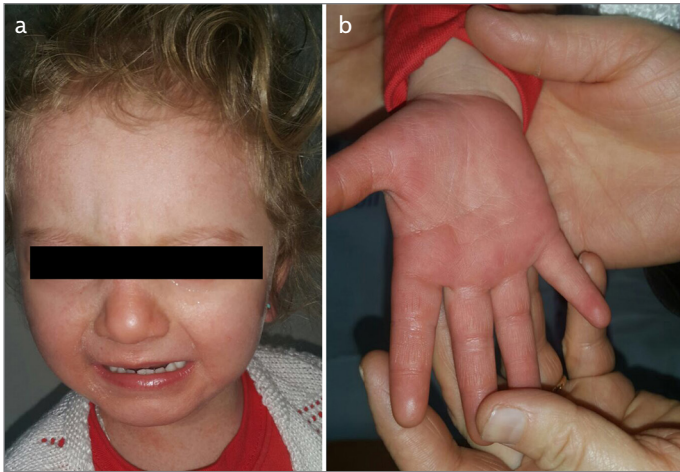
A 3-year-old girl was admitted because of a rash that began after she applied her mother's lipstick on her face.

### ÖZ

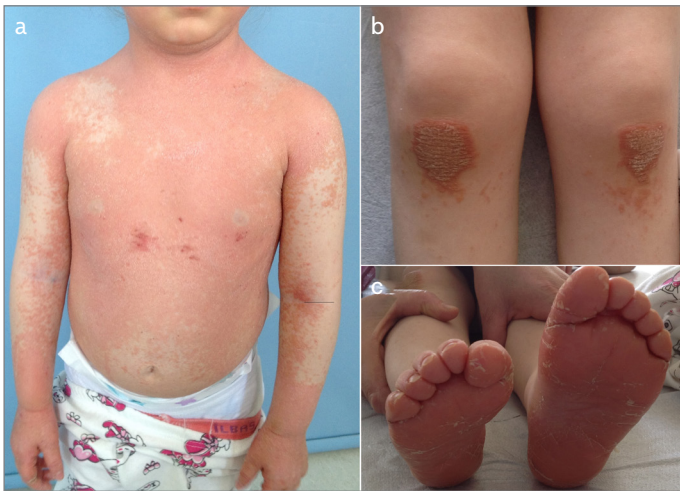Pitriyazis Rubra Pilaris (PRP), etyolojisi tam olarak bilinmeyen ve seyrek görülen bir papüloskuamöz hastalıktır. Hastalığın ortaya çıkma yaşı ve cilt tutulumuna göre altı tipi tanımlanmıştır. Tip 3 (klasik juvenil tip), tip 4 (juvenil varyant tip) ve tip 5 (atipik juvenil tip) juvenil formlardır. Burada Tip 3 PRP tanısı alan 3 yaşında bir kız çocuğu sunulmuştur. İlk başvuruda hastaya ruj temasına bağlı gelişen allerjik kontakt dermatit (AKD) tanısı ile topikal tedavi verildi ve 1 hafta içinde tamamen iyileşti. Hasta 10 gün sonra tüm vücutta yaygın döküntü ve palmoplantar keratoderma nedeniyle polikliniğimize tekrar başvurdu. Juvenil PRP ön tanısından şüphelenildi ve deri biyopsisi ile PRP tanısı doğrulandı. Ruj teması sonrası AKD ve klasik juvenil PRP ile prezente olan bir hasta sunduk ve biz bu hastada AKD'de olduğu gibi PRP gelişiminde de ruj temasının bir rolü olabileceğini düşünüyoruz

**Anahtar Kelimeler:** Kontakt dermatit, kozmetikler, pitriyazis rubra pilaris

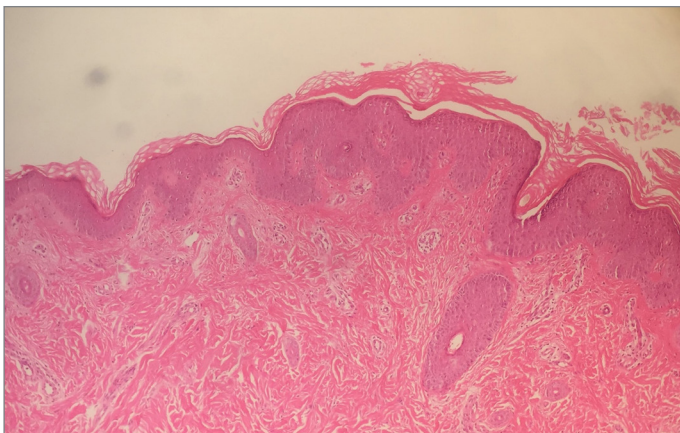
The patient had applied the lipstick once before and had presented with no complaints other than itching. It was found that there was no specific occurrence of the disease in her medical and family history. Her physical examination results were normal and her laboratory findings were within normal limits. Upon examination, erythema plaques all over her hands and face were noted (Figure 1). Topical, low-potency corticosteroids and an antihistamine syrup were prescribed upon prediagnosis of ACD. Within a week, she had recovered completely; however, 10 days later, the patient was readmitted to the hospital's outpatient clinic with a diffuse rash. Upon examination, orange-red psoriatic papules and plaques tended to merge on the patient's face, anterior and posterior



**Figure 1.** a, b. a, b) Erythematous plaques on her all face and hands



**Figure 2.** a-c. a) Psoriasiform plaques which tend to merge on the anterior and posterior trunk, b) Psoriasiform plaques on the bilateral knees, c) Plantar keratoderma



**Figure 3.** Follicular dilated openings, typical follicular plugging, diffuse orthokeratosis, and irregular acanthosis

trunk, bilateral upper extremities, and bilateral knees. Added to this, waxy keratoderma on the palms and soles of the feet were also noticed (Figure 2). A punch biopsy was performed on the patient, which revealed that the

formation of diffuse orthokeratosis, irregular acanthosis, follicular plugging, focal hypergranulosis, and perivascular lymphocytic infiltrate in the papillary dermis were compatible with PRP (Figure 3). With the diagnosis of classic juvenile PRP, the patient's treatment was supplemented with topical calcipotriol and moisturizing ointments. The patient showed improvement within 2 weeks and recovered completely within 2 months. She was still symptom-free 3 years after the treatment was discontinued. The patient's father has given a written consent for this case report.

## DISCUSSION

PRP is a rare dermatosis with an unknown etiology; however, vitamin A deficiency, thyroid dysfunction, UV exposure, trauma, and infections are considered to be the etiologic factors for the disease (3). For ACD, atopic dermatitis, skin barrier disturbance, and intense or recurrent contact with allergens are the trigger factors in children, and more often, shoes, clothes, toys, and cosmetics such as perfumes and lipsticks may cause ACD (4). The patient in this case report had no history of skin disease before; however, there was a history of intense contact with lipstick. A study conducted by Drechsel et al. (5) demonstrated that intense exposure to the fragrance chemicals found in cosmetics, such as lipsticks, eyeshadows, and solid antiperspirants, induces skin sensitivity. In this case, it is hypothesized that the exposure to lipstick might have facilitated the occurrence of PRP.

A positive result for allergens should be observed in the patch test for the diagnosis of ACD; if the presence of an allergen is not detected, differential diagnoses should be carefully reconsidered. In this patient's case, the patch test could not be performed as the family did not allow it. The exact diagnostic method for PRP is the histopathological examination; in histopathology, there is diffuse orthokeratosis with spotted parakeratosis (in a chessboard pattern) that also forms a collarette around the follicular ostia (6). Follicular dilated openings and some follicular plugging is often present (2), and perivascular and perifollicular lymphocytic cell infiltration occurs in the upper dermis. In this patient, the diagnosis of PRP was confirmed with a biopsy.

Shackelford and Belsito examined 704 patients who underwent patch testing within 5 years, retrospectively. Of these patients, 70 individuals presented with a diagnosis of contact dermatitis of the foot (7). Although clinical findings support the presence of allergies, only 23 of the 70 patients who were diagnosed with foot dermatitis reported contact dermatitis because of shoe allergens. Psoriasis was the primary diagnosis in 30 patients and 1 patient was diagnosed with PRP. In the literature research conducted, this study is the only publication found that

investigated the relationship between contact dermatitis and PRP.

Lipstick-related dermatitises, particularly ACD, have been reported in several publications (8–10); however, the occurrence of PRP in this patient, after an intense contact with lipstick, was surprising. In this case report, it was observed that, in children, cosmetics can trigger skin diseases, such as PRP, alongside ACD. It is suggested that limiting the use of cosmetics can prevent these diseases from occurring.

**Informed Consent:** A written consent was obtained from the patient's father.

**Peer-review:** Externally peer-reviewed.

**Author Contributions:** Concept - Ü.Ö.; Design - Ü.Ö.; Supervision - H.B.; Resources - Ü.Ö.; Materials - Ü.Ö.; Data Collection and/or Processing - Ü.Ö.; Analysis and/or Interpretation - Ü.Ö., H.B.; Literature Search - Ü.Ö.; Writing Manuscript - Ü.Ö.; Critical Review - H.B.

**Conflict of Interest:** Authors have no conflicts of interest to declare.

**Financial Disclosure:** The authors declared that this study has received no financial support.

**Hasta Onamı:** Hastanın babasından yazılı onam alınmıştır.

**Hakem Değerlendirmesi:** Dış bağımsız.

**Yazar Katkıları:** Fikir - Ü.Ö.; Tasarım - Ü.Ö.; Denetleme - H.B.; Kaynaklar - Ü.Ö.; Malzemeler - Ü.Ö.; Veri Toplanması ve/veya İşlemesi - Ü.Ö.; Analiz ve/veya Yorum - Ü.Ö., H.B.; Literatür Taraması - Ü.Ö.; Yazıyı Yazan - Ü.Ö.; Eleştirel İnceleme - H.B.

**Çıkar Çatışması:** Yazarlar çıkar çatışması bildirmemişlerdir.

**Finansal Destek:** Yazarlar tarafından finansal destek almadıkları bildirilmiştir.

## REFERENCES

1. Simonsen AB, Deleuran M, Johansen JD, Sommerlund M. Contact allergy and allergic contact dermatitis in children - a review of current data. *Contact Dermatitis* 2011; 65:254-65. [\[Crossref\]](#)
2. Chee SN, Lee S. Pityriasis rubra pilaris: Not just skin deep a case series. *Hong Kong J Dermatol Venereol* 2016; 24: 129-34.
3. Kamarachev J, Grozdev I, Darlenski R, Tsankov N. Pityriasis rubra pilaris as a systemic disease. *Clin Dermatol* 2019; 37: 657-62. [\[Crossref\]](#)
4. de Waard-van der Spek FB, Andersen KE, Darsow U, Mortz CG, Orton D, Worm M, et al. Allergic contact dermatitis in children: which factors are relevant? (review of the literature). *Pediatr Allergy Immunol* 2013; 24: 321-9. [\[Crossref\]](#)
5. Drechsel DA, Towle KM, Fung ES, Novick RM, Paustenbach DJ, Monnot AD. Skin sensitization induction potential from daily exposure to fragrances in personal care products. *Dermatitis* 2018; 29: 324-31. [\[Crossref\]](#)
6. Patterson JW. Weedon's skin pathology. In: Patterson JW, editor. 4th ed. Charlottesville: Churchill Livingstone; 2016.
7. Shackelford KE, Belsito DV. The etiology of allergic-appearing foot dermatitis: a 5-year retrospective study. *J Am Acad Dermatol* 2002; 47: 715-21. [\[Crossref\]](#)
8. Sowa J, Suzuki K, Tsurata K, Akamatsu H, Matsunaga K. Allergic contact dermatitis from propylene glycol ricinoleate in a lipstick. *Contact Dermatitis*. 2003; 48: 228-9. [\[Crossref\]](#)
9. Shono M. Allergic contact dermatitis from isopalmityl diglyceryl sebacate in lipsticks. *Contact Dermatitis* 2003; 48: 48-9. [\[Crossref\]](#)
10. Tran A, Pratt M, Dekoven J. Acute allergic contact dermatitis of the lips from peppermint oil in a lip balm. *Dermatitis* 2010; 21: 111-5. [\[Crossref\]](#)